

ORIGINAL
RESEARCH

A. Cerasa
D. Messina
G. Nicoletti
F. Novellino
P. Lanza
F. Condino
G. Arabia
M. Salsone
A. Quattrone

Cerebellar Atrophy in Essential Tremor Using an Automated Segmentation Method

BACKGROUND AND PURPOSE: Essential tremor (ET) is a slowly progressive disorder characterized by postural and kinetic tremors most commonly affecting the forearms and hands. Several lines of evidence from physiologic and neuroimaging studies point toward a major role of the cerebellum in this disease. Recently, voxel-based morphometry (VBM) has been proposed to quantify cerebellar atrophy in ET. However, VBM was not originally designed to study subcortical structures, and the complicated anatomy of the cerebellum may hamper the automatic processing of VBM. The aim of this study was to determine the efficacy and utility of using automated subcortical segmentation to identify atrophy of the cerebellum and other subcortical structures in patients with ET.

MATERIALS AND METHODS: We used a recently developed automated volumetric method (FreeSurfer) to quantify subcortical atrophy in ET by comparing results obtained with this method with those provided by previous evidence. The study included T1-weighted MR images of 46 patients with ET grouped into those having arm ET ($n = 27$, a-ET) or head ET ($n = 19$, h-ET) and 28 healthy controls.

RESULTS: Results revealed the expected reduction of cerebellar volume in patients with h-ET with respect to healthy controls after controlling for intracranial volume. No significant difference was detected in any other subcortical area.

CONCLUSIONS: Volumetric data obtained with automated segmentation of subcortical and cerebellar structures approximate data from a previous study based on VBM. The current findings extend the literature by providing initial validation for using fully automated segmentation to derive cerebellar volumetric information from patients with ET.

The cerebellar involvement in essential tremor (ET) pathology has mainly been proposed but never demonstrated.¹⁻³ In a recent voxel-based morphometry (VBM) study, patients within our group with a specific subtype of ET were shown to have cerebellar atrophy primarily involving the anterior vermis.⁴ VBM permits an automated voxel-wise whole-brain statistical comparison of MR images by using the statistical parametric mapping (SPM) software (Wellcome Department of Cognitive Neurology, London, UK). However, VBM was not originally designed for the analysis of subcortical structures, and the complicated anatomy of the cerebellum and the surrounding cerebral tissue may hamper the automatic processing of VBM.

Despite the limits of VBM methodology, an automated method with high reproducibility and accuracy may potentially be more efficient. Several automated volumetric methods have been developed. The FreeSurfer⁵ software package (<http://surfer.nmr.mgh.harvard.edu>) provides completely automated parcellation of the cerebral cortex and subcortical structures. FreeSurfer calculates brain subvolumes by assigning a neuroanatomic label to each voxel in an MR imaging volume, on the basis of probabilistic information estimated automatically from a manually labeled training set. Several studies have validated the use of this method to quantify subcortical volume in dementia,⁶ epilepsy,^{7,8} and depressive disorders⁹ and to evaluate the effects of aging.¹⁰

The aim of this work was, therefore, to determine the effi-

cacy and utility of using automatic segmentation labeling to quantify atrophy in patients with ET. More precisely, we investigated whether this technique provided results similar to VBM data⁴ and whether additional abnormalities in other subcortical regions, beyond the cerebellum might be detected.

Materials and Methods

Patients

Data were acquired twice from the same patients reported in our previous study.⁴ From 82 potential subjects (50 patients with a diagnosis of familial ET¹¹ and 32 healthy controls), 4 patients with ET and 4 healthy controls were excluded owing to MR imaging inaccuracy (see "MR Imaging Scanning and Image Processing"). Forty-six patients with ET (22 women, 48%; mean age, 67.3 ± 11.3 years) and 28 sex- and age-matched healthy controls (14 women, 50%; mean age, 66.5 ± 7.8 years) were enrolled in this study. All enrolled patients were from unrelated families and had at least a first-degree relative with ET. Tremor was quantified by using the Fahn-Tolosa-Marin Tremor Rating Scale, Part A (Fahn-TRS-A)¹² and the Brain scale.¹³ At the time of the study, 14 patients were not taking therapy, 16 patients were treated with a monotherapy (β -receptors antagonist or primidone), and 20 patients were taking multiple medications including benzodiazepine, β -receptor antagonists, and antiepileptic drugs. Subjects with a history of other neuropsychiatric disorders or alcohol or drug abuse were excluded. All subjects gave their written informed consent to participate in the study, which was approved by the local ethics committee.

MR Imaging Scanning and Image Processing

Brain MR imaging was performed according to our routine protocol by a 1.5T unit (Signa NV/I; GE Healthcare, Milwaukee, Wis). Two 3D T1-weighted spoiled gradient-echo sequences in succession (TR, 15.2 ms; TE, 6.7 ms; flip angle, 15°; matrix size, 256×256 ; FOV, 24 cm;

Received December 2, 2008; accepted after revision January 14, 2009.

From the Institute of Neurological Sciences (A.C., D.M., G.N., P.L., F.C., G.A., A.Q.), National Research Council, Piano Lago di Mangone, Cosenza, Italy; and Institute of Neurology (D.M., G.N., F.N., M.S., A.Q.), University "Magna Graecia," Catanzaro, Italy.

Please address correspondence to Aldo Quattrone, MD, Institute of Neurology, Department of Medical Sciences, University Magna Graecia, Catanzaro, Italy; e-mail: a.quattrone@isn.cnr.it

DOI 10.3174/ajnr.A1544

section thickness, 1.2 mm; scanning time, 12 minutes per volume) were run for all participants. The second scanning was registered to the first scanning by using rigid registration. The first scan and the coregistered second scan were subsequently averaged to create a single high-signal-intensity-to-noise average volume. With the subject supine, cushions were carefully packed around the head to limit motion. The image protocol was identical for all subjects studied.

The image files in DICOM format were transferred to a Linux workstation for morphometric analysis. Subcortical volume analysis was measured automatically by FreeSurfer 4.05 installed on a Red Hat Enterprise Linux v.5. The automated procedures for volumetric measures of these different brain structures have been described previously.⁵ This procedure automatically provided segments and labels for ≤ 40 unique structures and assigned a neuroanatomic label to each voxel in an MR imaging volume on the basis of probabilistic information estimated automatically from a manually labeled training set. Briefly, the segmentation is performed as follows: an optimal linear transform is computed that maximizes the likelihood of the input image, given an atlas constructed from manually labeled images. A nonlinear transform is then initialized with the linear one, and the image is allowed to further deform to better match the atlas. Finally, a Bayesian segmentation procedure is performed, and the maximum a posteriori estimate of the labeling is computed.

The segmentation uses 3 pieces of information to disambiguate labels: 1) the prior probability of a given tissue class occurring at a specific atlas location, 2) the likelihood of the image given that tissue class, and 3) the probability of the local spatial configuration of labels given the tissue class. This latter term represents a large number of constraints on the space of allowable segmentations and prohibits label configurations that never occur in the training set (eg, the hippocampus is never anterior to the amygdala). This technique has been validated against manual tracings in healthy individuals and patients with neurologic disease.^{5,7}

The segmentations were visually inspected for accuracy. Eight subjects' data (4 patients with ET and 4 controls) were discarded owing to image artifacts leading to inaccurate segmentation. Intracranial volume (ICV) was calculated and used to correct the regional brain volumes analyses. Given the recent evidence about the lower precision of FreeSurfer⁶ to estimate ICV than other fully automated segmentation techniques, we decided to calculate ICV by using SPM2 (<http://www.fil.ion.ucl.ac.uk/spm>). The SPM method was based on the subjects' segmented images in native space: gray matter, white matter, and CSF. The SPM procedure used the "Segment" button to extract the tissue maps in native space. Summing the probabilities of the images for gray and white matter provides a measure of "probable total brain volume"; adding CSF provides a measure of "probable total intracranial volume." When we correlated the 2 fully automated methods, a significant relationship was detected ($r = 0.803$, P level $< .0001$), confirming the tendency of FreeSurfer to overestimate ICV⁶ (mean of all 74 MR images: ICV on FreeSurfer, 1428.6 ± 138.6 mm³; ICV on SPM, 1411.4 ± 124.1 mm³).

Statistical Analysis

The significance of differences in the ICV and each neuroanatomic volume between controls and patients were tested by using the t test. Furthermore, to compare neuroanatomic volume, analysis of covariance (ANCOVA) was performed with the covariate ICV.⁹ Simple regression analysis was used to determine the contribution of disease-related factors (age at onset, disease duration, Fahn-TRS-A and Brain scales) with structural volume measurements. One-way analysis of

Table 1: Demographic and clinical characteristics in ET and control groups*

	h-ET	a-ET	Controls	P Value
Age	70.7 \pm 7.8	65 \pm 12.8	66.5 \pm 7.8	.15†
Sex (M/F)	6:13	17:10	14:14	.11‡
Age at onset (yr)	49.96 \pm 17.4	45.5 \pm 17.9		.41§
Disease duration (yr)	20.5 \pm 15	19.6 \pm 15.2		.83§
Fahn-TRS-A scale	13 (8–16)	9 (2–17)		.004
Brain scale	42 (30–66)	35 (28–65)		.01

Note:—ET indicates essential tremor; h-, head; a-, arm; TRS, Tremor Rating Scale.

* Data are given as mean values (\pm SD) or median values (range) when appropriate.

† One-way ANOVA, followed by unpaired t test corrected according to Bonferroni.

‡ χ^2 test.

§ Unpaired test.

|| Mann-Whitney U test.

variance (ANOVA), followed by unpaired t tests, corrected according to Bonferroni, were performed for comparison of the age at examination. The χ^2 test was used to compare sex distributions among groups. The differences in the mean of age at onset and disease duration between ET groups were assessed by using unpaired t tests, whereas for the Fahn-TRS-A and Brain scales, the Mann-Whitney U test was used. All statistical analyses had a 2-tailed α level of $< .05$ for defining significance.

Results

Forty-six patients with ET were grouped according to the presence or absence of head tremor. Twenty-seven of the 46 patients with ET had arm ET (a-ET; 10 women, 37%), whereas the remaining 19 patients had both a-ET and head ET (h-ET; 13 women, 68%). Any significant demographic differences have been detected between patients and controls (Table 1). Patients with h-ET scored higher in the Fahn-TRS-A scale (median value = 13; range, 8–16) and Brain scale (median value = 42; range, 30–66) than patients with a-ET (Fahn-TRS-A scale: median value = 9; range, 2–17; Brain scale: median value = 35; range, 28–65; $P = .004$ and $.01$, respectively).

Univariate analysis corrected for ICV revealed no significant volumetric difference in any subcortical areas between ET groups and healthy control subjects (Table 2), though some regions were mostly of borderline statistical significance. Given our previous VBM evidence⁴ highlighting the specific cerebellar involvement only in patients with h-ET, we decided to perform an exploratory post hoc analysis to confirm early data. Results revealed the expected reduction of cerebellum including gray matter ($P = .02$) and white matter volume ($P = .01$) in patients with h-ET with respect to healthy controls (Fig 1). No significant difference was observed among patients with a-ET with respect to other groups. We used linear regression to determine if key disease-related variables predicted volume loss in the structure that was atrophic in the patients with ET relative to the same structure in the controls. Results revealed no significant linear relationship between clinical variables and adjusted cerebellar volume in the h-ET group (all, $P > .1$).

Discussion

We report on the use of automated segmentation of subcortical and cerebellar structures for identifying a significant biomarker of the neurodegenerative processes in ET. Our data suggest that automated segmentation, as provided by FreeSurfer, reveals a pattern of atrophy similar to that obtained

Table 2: Volumes (mean) measured with an automated volumetric method (FreeSurfer)*

	h-ET (<i>n</i> = 19)	a-ET (<i>n</i> = 27)	Controls (<i>n</i> = 28)	<i>P</i> Values	
				<i>t</i> Test	ANCOVA
ICV	1375.8 ± 119.7	1434.7 ± 127.5	1411.9 ± 122.6	.22	
Cortical gray matter	393.8 ± 30.5	413.5 ± 49.5	404.1 ± 32.6	.13	.58
Cortical white matter	358.9 ± 41.1	385.3 ± 57.1	384.6 ± 41.9	.1	.29
Cerebellar gray matter	86 ± 7.1	89.6 ± 11.1	91.9 ± 8.2	.23	.15†
Cerebellar white matter	23.5 ± 3.3	23.9 ± 3	25.7 ± 4.2	.59	.06†
Thalamus	11.3 ± 1.2	12 ± 1.5	11.6 ± 1.3	.11	.49
Putamen	9.1 ± 0.9	9.6 ± 1.8	8.9 ± 1.1	.19	.18
Pallidum	2.9 ± 0.3	3 ± 0.5	2.9 ± 0.4	.54	.82
Caudate	6.6 ± 0.7	7.1 ± 1.3	6.5 ± 0.8	.11	.1
Hippocampus	6.8 ± 0.7	7.1 ± 1.1	7 ± 0.8	.31	.76
Lateral ventricle	22.9 ± 14.7	25.9 ± 15.9	21.5 ± 12.8	.51	.55
Third ventricle	1.5 ± 0.7	1.4 ± 0.5	1.4 ± 0.6	.85	.42
Fourth ventricle	1.7 ± 0.6	1.9 ± 0.6	1.7 ± 0.6	.21	.29
Brain stem	18.4 ± 1.9	18.8 ± 2.1	19.3 ± 2.2	.54	.32

Note:—ICV, indicates intracranial volume.

* For each neuroanatomic volume, ANCOVA statistical test covariate with ICV is performed.

† Significant difference after post hoc analysis between h-ET and control groups, performed with the Duncan *t* test. Volumes are in cubic millimeters.

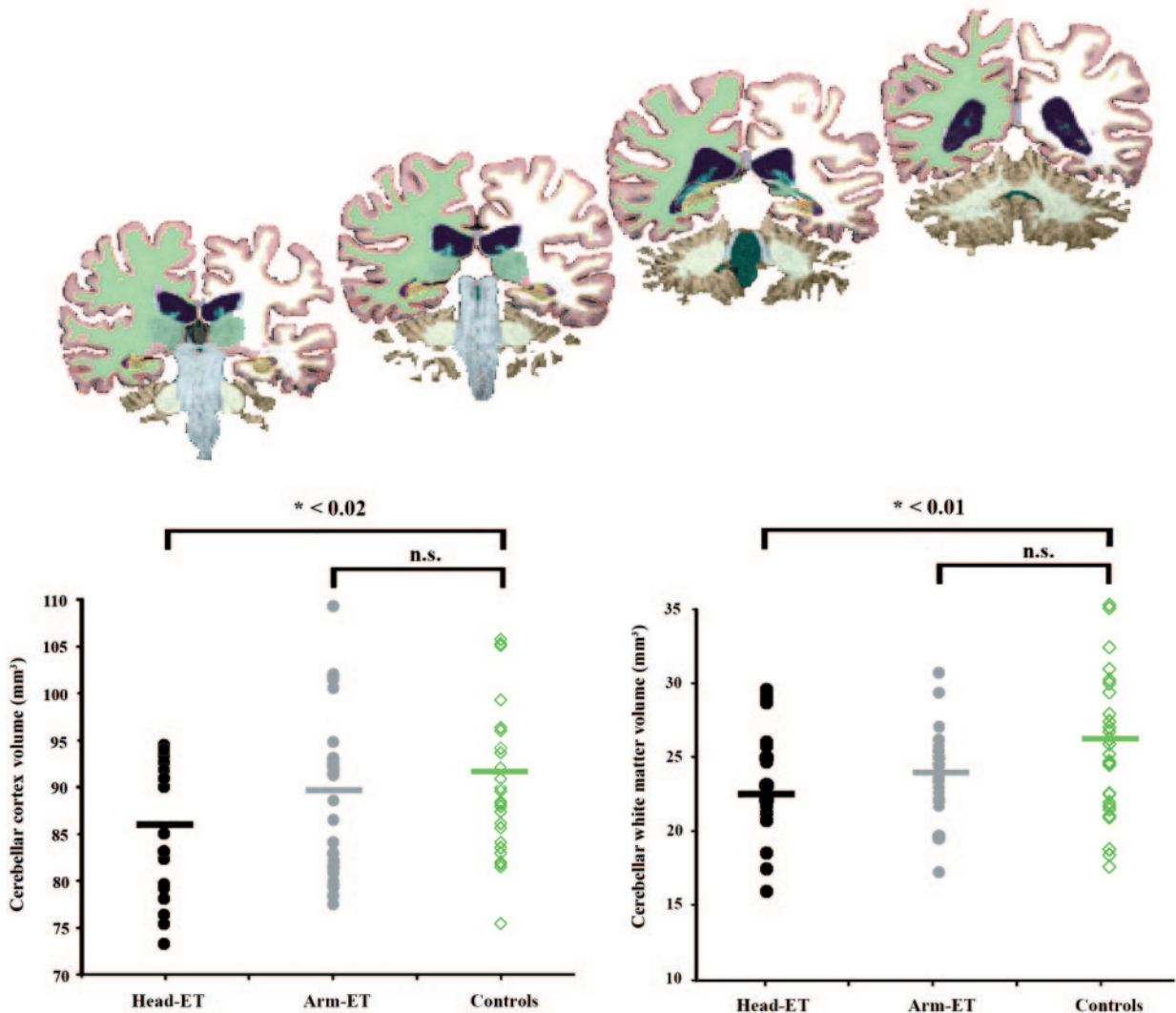


Fig 1. Automated labeling of the cerebellum as provided by FreeSurfer. From bottom to top, sections 92, 101, 106, and 110 in the coronal view are shown, respectively. The different structures have unique color codes. After correcting for ICV, MR imaging volumetry using subcortical segmentation reveals cerebellar atrophy in the h-ET group with respect to the controls for absolute gray matter and white matter volumes: mean, respectively: h-ET = 86 ± 7.1 and 23.5 ± 3.3 mm³; a-ET = 89.6 ± 11.1 and 23.9 ± 3 mm³; healthy controls = 91.9 ± 8.2 and 25.7 ± 4.2 mm³.

with VBM and manual tracings.⁴ Among all the studied volumes, FreeSurfer showed the presence of atrophy only in the cerebellum and showed this atrophy occurring only in a specific subtype of ET (h-ET). This finding confirms evidence provided by our previous VBM study,⁴ in which any significant voxel-by-voxel change (increased or decreased) has been found in the whole brain except for a cluster localized in the anterior vermis, which becomes volumetrically (modulation step) reduced only when comparing patients with h-ET with controls.

Although VBM involves spatial deformation to register all the scans into a common space, the current evidence demonstrates that VBM spatial deformation correctly handles the principal distortions in the subcortical gray nuclei and cerebellum. Thus, optimized VBM¹⁴ may represent a sensitive surrogate marker because it provides a reliable objective quantification of atrophy in patients with ET. Damage to the cerebellum has also been confirmed by using a manual volumetric region-of-interest approach (MREG software; available at: www.erg.ion.ucl.ac.uk/MRreg.html).⁴ However, the manual cerebellar volumetry is time-consuming and dependent on rater experience; thus, automated methods with high reproducibility and accuracy may potentially be more efficient than manual tracings. Although the automated cerebellar volumetry using FreeSurfer has been validated in patients with epilepsy,⁷ a direct comparison between automated and manual measurements of the cerebellum in ET could better clarify the exact reliability of our data.

The detected cerebellar volume in patients with h-ET was a few percentage points lower than that of the controls (~7%), reaching a moderate statistical threshold. This decrease may depend on 3 factors: 1) The evidence provided by VBM analysis⁴ defines a small cerebellar involvement including only the anterior lobule of vermis. 2) ET is not a uniform disorder characterized by a high heterogeneity in clinical phenotypes,¹⁵ which may affect the magnitude of the detected volumetric change. 3) Our patient sample size was relatively small. As a result, our study may have been underpowered to detect subtle volume loss in some structures.

Another important finding reported by this study is the lack of significant association between clinical findings and the detected cerebellar atrophy. Even if patients with h-ET scored higher on the Fahn-TRS-A and the Brain scales, any significant association was detected with the cerebellar volume loss. Again, the lack of correlation is in agreement with the regression analysis executed in a previous VBM study from our group.⁴ All the aforementioned evidence, together with the fact that the detected cerebellar atrophy has been found in familial ET, support the view that a genetic background is implicated in the genesis of cerebellar atrophy.

However, FreeSurfer has limitations. In fact, given the inherent limitations of any fully automated segmentation soft-

ware, cortical and subcortical labeling may be influenced by several factors, such as section thickness, MR imaging noise level, MR imaging orientation, field strength, and anatomic boundary criteria. However, the exact correspondence between the findings provided by this automated method and those related to manual tracing and voxel-based analysis⁴ underscores the utility of this method.

Conclusions

We successfully demonstrated the presence of cerebellar atrophy in patients with h-ET by using an automated segmentation approach. This finding confirms previous voxel-based and manually traced findings,⁴ highlights the involvement of the cerebellar region in the pathophysiology of ET, and suggests that a-ET and h-ET may be distinct clinical subtypes of the same disease.

Acknowledgments

We thank Maurizio Morelli and Sandra Paglionico for help with clinical data acquisition and Andrea Cherubini for helpful methodologic suggestions.

References

1. Louis ED, Vonsattel JP, Honig LS, et al. **Essential tremor associated with pathologic changes in the cerebellum.** *Arch Neurol* 2006;63:1189–93
2. Louis ED. **Essential tremor.** *Lancet Neurol* 2005;4:100–10
3. Daniels C, Peller M, Wolff S, et al. **Voxel-based morphometry shows no decreases in cerebellar gray matter volume in essential tremor.** *Neurology* 2006;67:1452–56
4. Quattrone A, Cerasa A, Messina D, et al. **Essential head tremor is associated with cerebellar vermis atrophy: a volumetric and voxel-based morphometry MRI study.** *AJNR Am J Neuroradiol* 2008;29:1692–97
5. Fischl B, Salat DH, Busa E, et al. **Whole brain segmentation: automated labeling of neuroanatomical structures in the human brain.** *Neuron* 2002;33:341–55
6. Pengas G, Pereira JM, Williams GB, et al. **Comparative reliability of total intracranial volume estimation methods and the influence of atrophy in a longitudinal semantic dementia cohort.** *J Neuroimaging* 2009;19:37–46. Epub 2008 May 19
7. McDonald CR, Hagler DJ Jr, Ahmadi ME, et al. **Subcortical and cerebellar atrophy in mesial temporal lobe epilepsy revealed by automatic segmentation.** *Epilepsy Res* 2008;79:130–38
8. McDonald CR, Hagler DJ Jr, Ahmadi ME, et al. **Regional neocortical thinning in mesial temporal lobe epilepsy.** *Epilepsia* 2008;49:794–803
9. Tae WS, Kim SS, Lee KU, et al. **Validation of hippocampal volumes measured using a manual method and two automated methods (FreeSurfer and IBASPM) in chronic major depressive disorder.** *Neuroradiology* 2008;50:569–81. Epub 2008 Apr 15
10. Walhovd KB, Fjell AM, Reinvang I, et al. **Effects of age on volumes of cortex, white matter and subcortical structures.** *Neurobiol Aging* 2005;26:1261–70
11. Deuschl G, Bain P, Brin M. **Consensus statement of the Movement Disorder Society on Tremor: Ad Hoc Scientific Committee.** *Mov Disord* 1998;13:2–23
12. Fahn S, Tolosa E, Marin C. **Clinical rating scale for tremor.** In: Jankovic J, Tolosa E, eds. *Parkinson's Disease and Movement Disorders*. Baltimore: Lippincott Williams & Wilkins; 1993
13. Bain PG, Findley LJ, Atchison P, et al. **Assessing tremor severity.** *J Neurol Neurosurg Psychiatry* 1993;56:868–73
14. Good CD, Johnsrude IS, Ashburner J, et al. **A voxel-based morphometric study of ageing in 465 normal adult human brains.** *Neuroimage* 2001;14(1 pt 1): 21–36
15. Louis ED, Ford B, Barnes LF. **Clinical subtypes of essential tremor.** *Arch Neurol* 2000;57:1194–98